Asymptomatic rectal and bladder endometriosis: a case for robotic-assisted surgery

Mario F. Chammas Jr., MD,[1] Fernando J. Kim, MD,[1] Aurelio Barbarino, MD,[2] Nicolas Hubert, MD,[3] Benoît Feuillu, MD,[3] Alain Coissard, MD,[4] Jacques Hubert, MD[3]

[1]Denver Health Medical Center, University of Colorado Health Sciences Center, Denver, Colorado, USA
[2]Gynecology Department, Regional Maternity, CHU Nancy, France
[3]Urology Department, CHU Nancy – Brabois, Nancy, France
[4]Department of Anesthesia, CHU Nancy – Brabois, Nancy, France

CHAMMAS JR MF, KIM FJ, BARBARINO A, HUBERT N, FEUILLU B, COISSARD A, HUBERT J. Asymptomatic rectal and bladder endometriosis: a case for robotic-assisted surgery. The Canadian Journal of Urology. 2008;15(3):0000-0000.

Objectives: *To evaluate the feasibility and safety of robot-assisted laparoscopic partial cystectomy for the treatment of rectal and bladder endometriosis.*
Materials and methods: *A 23 year-old female with history of infertility and pelvic pain was found to have a 4 cm bladder mass and rectal nodule on pelvic ultrasonography. Patient denied any other genitourinary symptoms.*
Cystoscopy and bladder mass biopsy revealed endometriosis. After failure to suppressive hormonal medical therapy a partial cystectomy and resection of a rectal lesion was performed with robotic assistance (da Vinci). The procedure included excision of an ovarian cyst and several peritoneal endometrioid implants.
Results: *Robotic-assisted (da Vinci) partial cystectomy with concomitant excision of endometrial nodules from the rectum and ovarian cyst was performed in 185 min. The rectal lesion was excised and primary closure of the rectum was performed. Patient had an uneventful postoperative course and hospital stay. Oral intake was started on postoperative day 1 and follow-up imaging revealed no bladder extravasation or fistula formation. The patient became pregnant 2 years later with "in vitro" fertilization procedure.*
Conclusions: *Robotic-assisted laparoscopic partial cystectomy with excision of rectal nodules for endometriosis can be safely performed.*

Key Words: laparoscopy, partial cystectomy, robotics, endometriosis

Introduction

Bladder endometriosis is an uncommon clinical entity, occurring in less than 1% of patients presenting with endometriosis.[1] Occasionally, deep pelvic endometrioid infiltration may coexist, including rectal endometriosis.[2]

Accepted for publication March 2008

Address correspondence to Dr. Mario F. Chammas, Jr., University of Colorado Health Sciences Center, Denver Health Medical Center, Urology Department, MC-0206, 777 Bannock St, Denver, CO 80204 USA

Treatment options include suppressive hormonal therapy, hysterectomy, oophorectomy, cystoscopic electrocoagulation, and excision of endometrial lesions; i.e., partial cystectomy.[3]

In recent years, due to new minimally invasive surgical techniques the traditional open surgery (partial cystectomy) may be performed laparoscopically.[4]

Reports of the laparoscopic and robotic approaches have demonstrated to be efficient and to offer faster recovery and better cosmetic results than the open surgery.[5,6] To our knowledge, we report the feasibility and safety of the first case of robotic assisted laparoscopic partial cystectomy and excision of rectal nodules for bladder and rectal endometriosis with



Figure 1. Preoperative cystoscopic evaluation.

repair of the rectal wall using the daVinci system (Intuitive Surgical, Sunnyvale, CA, USA).

Case report

A 23 year-old female presented with a solid mass in the posterior bladder wall with an associated ovarian cyst found incidentally during pelvic ultrasound as part of the work up for infertility and pelvic pain. The patient had no genitourinary symptoms and urinalysis was normal.

Cystoscopy, Figure 1, and bladder mass biopsy (4 cm nodule in the posterior wall of the bladder;) confirmed the diagnosis of bladder endometriosis, Figure 2. The patient was initially managed with medical therapy (LHRH agonist therapy) for 8 months with no change in size of the bladder mass.

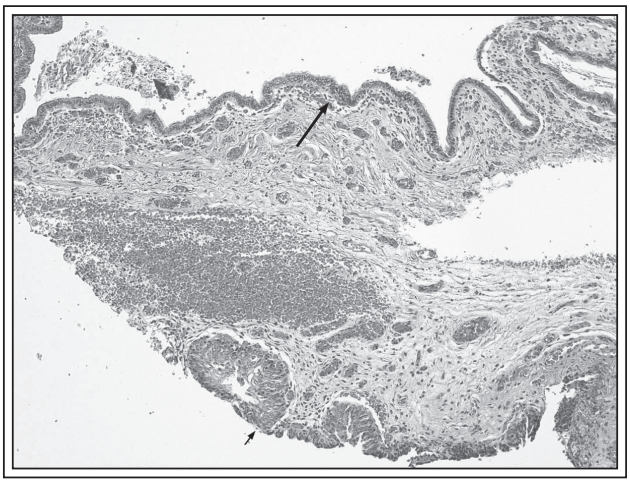

Figure 2. Hematoxiline-Eosine x10. Presence of urothelium (small arrow) and endometrial gland (large arrow).

Imaging studies included pelvic magnetic resonance imaging, which demonstrated the presence of 4 cm mass in the posterior bladder wall, Figure 3 and an intravenous pyelography (IVP) revealed normal bilateral renal and ureteral anatomy.

After discussing management options with the patient, hystero-salpingography and robotic assisted laparoscopic partial cystectomy with excision of an ovarian cyst, rectal and peritoneal endometrial implants was performed.

Surgical procedure

Bimanual pelvic exam under general anesthesia confirmed the presence of a palpable mobile mass. A cystoscopy and bilateral ureteral catheterization were performed to identify the ureters during the procedure. A hystero-salpingography was performed revealing a patent tract. Ports were placed as demonstrated in Figure 4.

A total of four trocars were used: two trocars of 10 mm for the robotic arms (at the right and left iliac fossa, about 3 cm medial to the anterior iliac spine), one 12 mm umbilical trocar for the camera and another 12 mm trocar at the left flank for the assistant.

Intraoperative findings demonstrated numerous small endometrioid lesions adjacent to the left ovary and the anterior rectal wall. A large left ovarian cyst was identified. The peritoneum was incised and dissection between the uterus and the bladder allowed access to the pouch of Douglas. The bladder was incised using the monopolar hook electrocauthery and a bipolar forceps. The bladder lesion was completely excised, Figure 5.

Cystorraphy was performed using one layer of running 2.0 vicryl. The bladder was irrigated with > 250 cc of sterile saline through the urethral catheter to identify leakage.

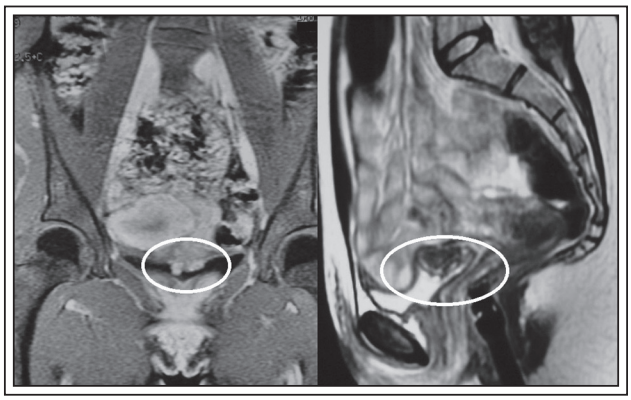

Figure 3. Nuclear magnetic resonance showing the vesical nodule.

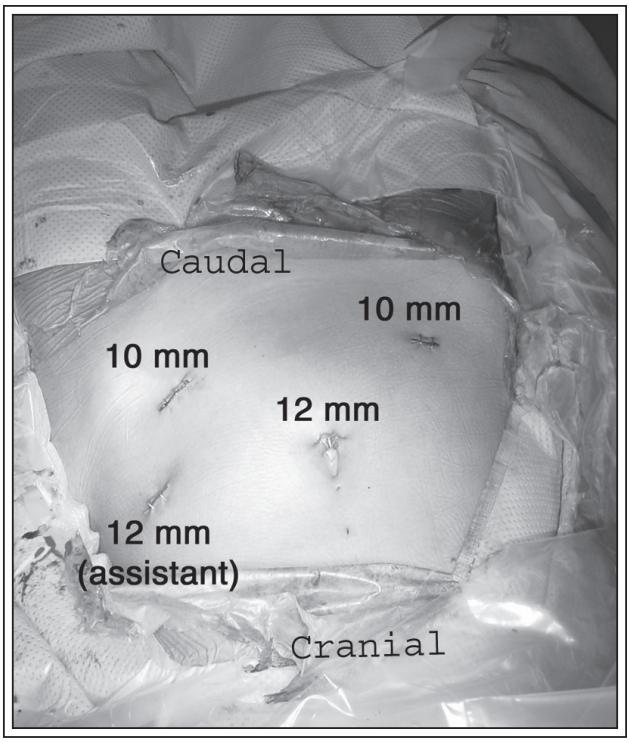

Figure 4. Port placement.

The left ovarian cyst was then dissected and excised. Small endometrioid lesions were burned using the bipolar forceps. Finally, the 1.5 cm nodule on the anterior wall of the rectum was excised and the rectal wall was repaired in two layers using running 3.0 vycril sutures. A Jackson Pratt drain was placed in the pelvis under laparoscopic guidance.

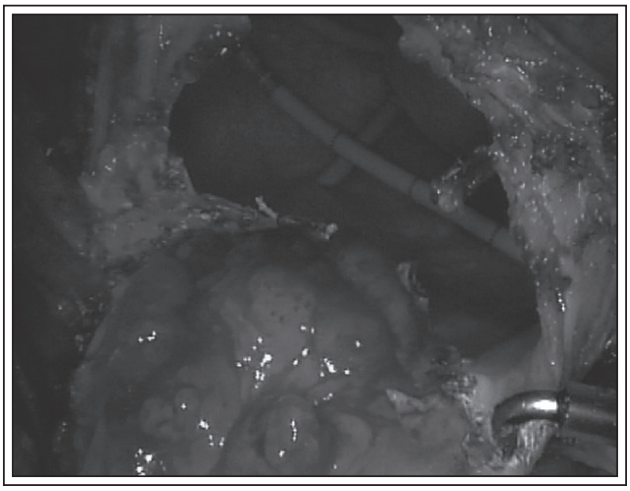

Figure 5. Intraoperative view and ressection of vesical lesion.

The peritoneum was closed with a continuous vicryl 4/0 suture. The specimens were placed inside the retrieval bag and brought out through one of the 12 mm port.

Results

Total operative time was 185 minutes (50 min for the partial cystectomy) and estimated blood loss was less than 100 ml.

The postoperative course was uneventful. Patient was ambulatory and resumed oral intake on postoperative day. The urethral catheter was removed 8 days after surgery. Pain control was achieved with non steroidal anti inflammatory medication.

Postoperative follow-up (24 months) revealed well healed port sites with satisfactory cosmetic results. Histopathology revealed bladder and rectal endometriosis. The patient became pregnant (IVF-ICSI) 2 years later and gave birth to a 3.300 kg normal boy.

Discussion

Endometriosis, a fairly common gynecological disease, consists of the presence of endometrial stroma outside the uterine cavity. It occurs in approximately 10% to 15% of premenopausal women.[7] The most frequent sites for implantation are the ovaries, uterosacral ligaments, fallopian tubes, cervix, vagina and cul-de-sac.[8] The urinary tract can be affected in approximately 1% to 2% of cases,[9] with a concomitant rectovaginal adenomyosis occuring in up to 45% of these patients.[10]

Bladder endometriosis was first described by Judd in 1921.[11] It occurs in less than 1% of patients presenting with endometriosis[1] and the diagnosis can be challenging.

Clinical presentation is variable, with the pathognomonic cyclical gross hematuria present only in 20% of patients.[12] Furthermore, the symptoms can be similar to those of recurrent cystitis in some cases.[13]

The management of endometriosis of the urinary tract is controversial. Due to the rarity of this condition large studies comparing the efficacy the various medical regimens and the surgical therapy are lacking.[12] Treatment varieties include suppressive hormonal therapy, hysterectomy, oophorectomy, cystoscopic electro coagulation, and segmental cystectomy.[3] Several reports recommend the surgical therapy when medical management fails.[9]

Usually, the bladder endometriomas are transmural, transurethral resection remains contraindicated due to the high risk of bladder perforation[12] or recurrence of the disease.[14]

Open partial cystectomy remains a commonly performed surgery for bladder endometriosis, as reported by Skor.[15]

Parra described the first laparoscopic cystectomy[16] and vesical diverticulectomy[17] introducing the minimally invasive approach for bladder surgery. Later, in 1993 both Ferzli[18] and Nezhat3 reported successful partial cystectomies for the management of bladder endometriosis.

This was followed by other series demonstrating faster recovery time and better cosmetic results compared to the open surgery.[6,19]

Even for deep infiltrating endometriosis the laparoscopic approach seems to demonstrate favorable results.[20] In the presence of a rectal lesion several authors suggests a more extensive surgery, including segmental and subtotal resections,[21,22] but a more conservative approach with local excision has also been demonstrated to be a safe and effective option.[20]

Several investigators have reported the feasibility and efficacy of the robotic assisted laparoscopic approach for pelvic surgeries.[23-26] Furthermore, recently Rabah et al have described a robot-assisted technique for an extended partial cystectomy with en bloc umbilectomy for the management of urachal carcinoma in a 49-year-old man with favorable results.[27]

To our knowledge, we report the first case of robotic assisted laparoscopic excision of rectal and bladder endometriosis with partial cystectomy, rectal nodule excision and rectal wall repair.

In summary, ablative and reconstructive steps of the surgical procedure can be easily achieved with the aid of the robotic system to allow surgeon to perform complex laparoscopic procedures.

Conclusion

This case report demonstrates the feasibility of the robotic laparoscopic approach to effectively manage rectal and bladder endometriomas allowing faster patient recovery and optimal cosmetic results. □

References

1. Shook TE, Nyberg LM. Endometriosis of the urinary tract. *Urology* 1988;31:1-6.
2. Hilaris GE, Payne CK, Osias J et al. Synchronous rectovaginal, urinary bladder, and pulmonary endometriosis. *Jsls* 2005;9:78-82.
3. Nezhat CR, Nezhat FR. Laparoscopic segmental bladder resection for endometriosis: a report of two cases. *Obstet Gynecol* 1993;81:882-884.
4. Langebrekke A, Istre O, Busund B et al. Endoscopic treatment of deep infiltrating endometriosis (DIE) involving the bladder and rectosigmoid colon. *Acta Obstet Gynecol Scand* 2006;85:712-715.
5. Panel P, Chis C, Gaudin S et al. Laparoscopic surgery of deep endometriosis. About 118 cases. *Gynecol Obstet Fertil* 2006;34:583-592.
6. Busacca M, Fedele L, Bianchi S et al. Surgical treatment of recurrent endometriosis: laparotomy versus laparoscopy. *Hum Reprod* 1998;13:2271-2274.
7. Hasson HM. Incidence of endometriosis in diagnostic laparoscopy. *J Reprod Med* 1976;16:135-138.
8. Williams TJ, Pratt JH. Endometriosis in 1,000 consecutive celiotomies: incidence and management. *Am J Obstet Gynecol* 1977;129:245-250.
9. Westney OL, Amundsen CL, McGuire EJ. Bladder endometriosis: conservative management. *J Urol* 2000;163:1814-1817.
10. Donnez J, Spada F, Squifflet J, Nisolle M. Bladder endometriosis must be considered as bladder adenomyosis. *Fertil Steril* 2000;74:1175-1181.
11. Judd ES. Adenomyoma presenting as a tumor of the bladder. *Surg Clin North Am* 1921;1:1271.
12. Nezhat CH, Malik S, Osias J et al. Laparoscopic management of 15 patients with infiltrating endometriosis of the bladder and a case of primary intravesical endometrioid adenosarcoma. *Fertil Steril* 2002;78:872-875.
13. Sircus SI, Sant GR, Ucci AA Jr. Bladder detrusor endometriosis mimicking interstitial cystitis. *Urology* 1988;32:339-342.
14. Antonelli A, Simeone C, Canossi E et al. Surgical approach to urinary endometriosis: experience on 28 cases. *Arch Ital Urol Androl* 2006;78:35-38.
15. Skor AB, Warren MM, Mueller EO, Jr. Endometriosis of bladder. *Urology* 1977;9:689-692.
16. Parra RO, Andrus CH, Jones JP, Boullier JA. Laparoscopic cystectomy: initial report on a new treatment for the retained bladder. *J Urol* 1992;148:1140-1144.
17. Parra RO, Jones JP, Andrus CH, Hagood PG. Laparoscopic diverticulectomy: preliminary report of a new approach for the treatment of bladder diverticulum. *J Urol* 1992;148:869-871.
18. Ferzli G, Wenof M, Giannakakos A et al. Laparoscopic partial cystectomy for vesical endometrioma. *J Laparoendosc Surg* 1993;3:161-165.
19. Fedele L, Bianchi S, Zanconato G et al. Long-term follow-up after conservative surgery for bladder endometriosis. *Fertil Steril* 2005;83:1729-1733.
20. Donnez J, Squifflet J. Laparoscopic excision of deep endometriosis. *Obstet Gynecol Clin North Am* 2004;31:567-580, ix.
21. Ferrero S, Ragni N, Remorgida V. Post-operative digestive symptoms after colorectal resection for endometriosis. *Hum Reprod* 2006;21:1941-1942; author reply 2-3.
22. Jatan AK, Solomon MJ, Young J et al. Laparoscopic management of rectal endometriosis. *Dis Colon Rectum* 2006;49:169-174.
23. Menon M, Hemal AK, Tewari A et al. Nerve-sparing robot-assisted radical cystoprostatectomy and urinary diversion. *BJU Int* 2003;92:232-236.
24. Menon M, Hemal AK, Tewari A et al. Robot-assisted radical cystectomy and urinary diversion in female patients: technique with preservation of the uterus and vagina. *J Am Coll Surg* 2004;198:386-393.
25. Yohannes P, Puri V, Yi B et al. Laparoscopy-assisted robotic radical cystoprostatectomy with ileal conduit urinary diversion for muscle-invasive bladder cancer: initial two cases. *J Endourol* 2003;17:729-732.
26. Yohannes P, Khan A, Francis K, Sudan R. Robot-assisted Bricker ileoureteral anastomosis during intracorporeal laparoscopic ileal conduit urinary diversion for prostatocutaneous fistula: case report. J Endourol 2004;18:269-272.
27. Rabah DM. Robot-assisted partial cystectomy for the treatment of urachal carcinoma. *Can J Urol* 2007;14:3640-3642.